

SMART DIAGNOSTIC SYSTEM FOR CLASSIFICATION OF DIABETICRETINOPATHY USING IMAGE PROCESSING TECHNIQUES

P. R. PATEL¹ & D. J. SHAH²

¹Research Scholar, Ganpat University, Ganpat Vidyanagar, Gujarat, India

²Director, Sankalchand Patel University, Visnagar, Gujarat, India

ABSTRACT

Diabetic Retinopathy is most normal retinal maladies. Diabetic Retinopathy (DR) is a dynamic retinal malady and ought to be distinguished as right on time as could be allowed. To help the ophthalmologists in mass screening of diabetes licenses, the keen identification and determination of Diabetic Retinopathy (DR) is intense to spare the patient's vision and. We display another shrewd framework for identification and arrangement of various DR sores i.e. smaller scale aneurysms (MAs), Haemorrhage (H), Hard Exudates (HE), and Cotton Wool Spots (CWS) in this paper. We proposed another brilliant framework in which every conceivable sore present in a fundus picture prosecuting Gabor channel bank by division. Every sore followed by components sets and distinctive properties for the order of injuries. With the assistance of disparate execution parameter and the outcomes, the evaluation of proposed framework are performed utilizing retinal picture data bases demonstrating the acknowledgment of proposed framework.

KEYWORDS: Catchphrases, Diabetic Retinopathy, Exudates, Haemorrhages, Small Scale Aneurysms and Retinal

I. INTRODUCTION

Diabetes influences verging on each one out of ten individuals, and has related complex, for example, vision harm, heart disappointment and stroke [1]. Diabetic eye malady makes reference to a gathering of eye issues that individuals with diabetes may confront as an intricacy. Patients with diabetes are more anticipated that would create eye issues, for example, waterfalls and glaucoma, however the sicknesses resolved to the retina is the principle danger to vision [2]. Entanglement of diabetes, bringing on peculiarity in the retina and in the most pessimistic scenario visual deficiency or thorough vision misfortune, is called Diabetic Retinopathy [2]. Diabetic retinopathy is the outcome of small scale vascular retinal changes. In a few people with diabetic retinopathy, veins may puff and release liquid. In other, new anomalous veins develop on the surface of the retina [3].

DR is a dynamic infection in which different sorts of sores begin showing up on the surface of retina with the concentrate of time that is the reason making an early disclosure and treatment is extremely intense. DR is comprehensively grouped into two phases i.e. Foundation DR or Non proliferative DR (NPDR) and proliferative DR (PDR). In this article, we are thinking about NPDR just since it incorporates early indications of DR. Human retina include diverse parts like veins, fovea, macula and optic circle (OD). NPDR happens when diabetes harms the veins inside the retina coming about spillage of blood and liquid on retina [4]. The retina then changes into wet and puffed and can't work legitimately. In NPDR diverse indications of retinopathy can happens, for example, Micro aneurysms (MAs), Haemorrhages (H), Hard Exudates (HE) and Soft Exudates or Cotton Wool Spots (CWS) [5].

Various techniques for individual finding of various DR injuries have been introduced. MAs are the principal obvious indication of DR which seen on the surface of retina that is the reason most

Studies spotlight on early location of DR by discovering MAs. Retinopathy Online Challenge (ROC) is a MA revelation rivalry began by University of Iowa [6] and the outcomes for first rivalry are given in [7]. An ideal wavelet change based technique for demonstrating and disclosure of MAs is proposed in [8]. A dataset of 120 pictures with MAs is utilized for assessment and summed up Gaussian layout is utilized for adjusting of MAs. Water et al. [9] proposed a thickness based regulated classifier for finding of MAs from applicant districts which are inferred utilizing morphological operations. Other than MAs, various techniques have introduced distinctive calculations for computerized location of exudates. The quantity of properties like luminance channel, nearby deviation in a sliding window and watershed change are used to extricate hard exudates in [10]. Highlight extraction utilizing higher request spectra and grouping utilizing SVM is proposed as a part of [11] for NPDR and PDR discovery with sensible flawlessness for various stages.

The lingering paper is sorted out as takes after: Section II covers brief surveys of around as of late distributed business related to NPDR. A graphical unique and layout of proposed framework are given in area III. It quickly clarifies the complete frameworks and its different stages. At that point in area IV and segment V, the means for damage extraction and their representation with help of highlight vectors are clarified. The clarification about classifier is portrayed in area VI conforms to results in segment VII. The last segment outlines the paper.

II. SYSTEM OVERVIEW

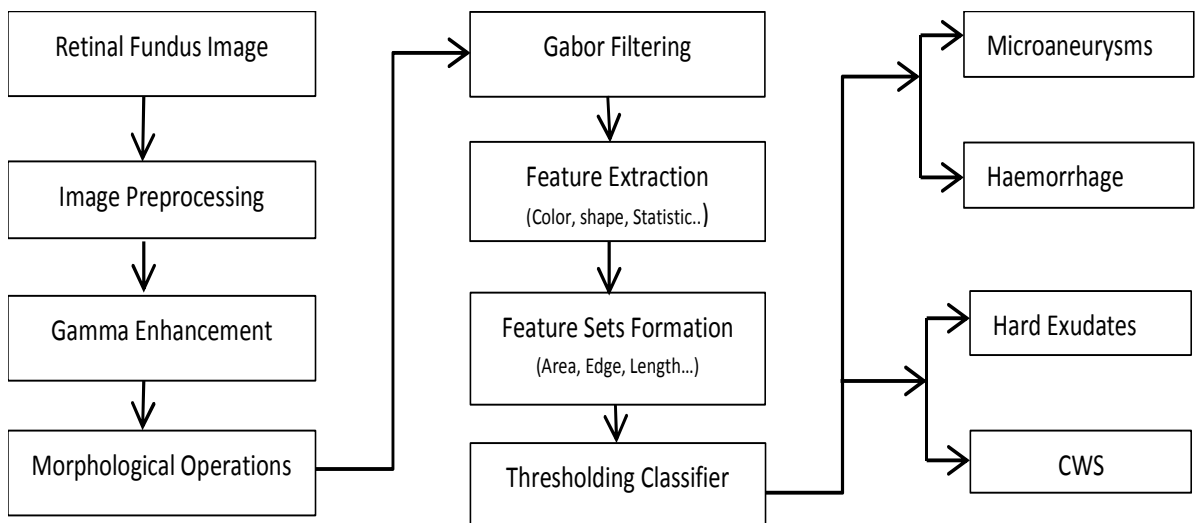


Figure 1: Flow Diagram for Proposed Non Proliferative Diabetic Retinopathy (NPDR) Classification System

This paper introduces a framework for grouping of executes present in retinal picture. The framework can be further utilized as a screening framework yet here we are just concentrating on flawless variation from the norm discovery. Figure 1 demonstrates a graphical perspective of the whole framework.

There are three phase of the proposed framework. I.e. picture obtaining and pre-handling, sores insertion and list of capabilities development lastly acknowledgment of genuine injuries utilizing characterization stage. The reason for pre-handling is to wipe out foundation locale and boisterous pixels from retinal picture to enhance the productivity of proposed framework. The brief work for pre-preparing utilized as a part of this framework is given in [12]. After

pre-handling, sores are improved and divided utilizing gamma upgrade strategy and Gabor channel banks. At long last, the classifier isolates out the injuries into four classes.

III. APPLICANT LESION RECOGNITION

The applicant injury discovery stage separates every single existing sore from information retinal picture. The MAs and H show up as red or dull dabs in shading or dark picture individually though HE and CWS are by all accounts yellowish or brilliant spots. In applicant injury discovery, we utilize their regular elements and distinguish them in two gatherings i.e. red sores and splendid sores. Then again, the classifier utilizes their more nitty gritty noticeable quality given in next area to further partition the competitor sores into four classes.

MAs and H otherwise called red damages show up as dim and red spots in dim and shading retinal pictures individually [10]. In initial step of hurt location, morphological opening is connected to save low power districts just if present utilizing condition 1 [10]

$$\phi_r^{(SB)} = \max [\min f(x + b)] \quad (1)$$

This gives us a retinal picture of which comprises of low force districts just (MAs, H, macula and vessels) abruptly frame which likewise require gamma improvement.

$$g = 255 \left[\Phi_w(\phi_r) - \Phi_w(\phi_{fmin}) \right] \left[\Phi_w(\phi_{rmax}) - \Phi_w(\phi_{fmin}) \right] \quad (2)$$

Where Φ_w is the sigmoid function

$$\Phi_w(\phi f) = [1 + \exp(mw - f)]^{-1} \quad (3)$$

σw

Figure-2 shows the outputs for morphological and gamma enhancement operations.

The enhanced image is passed through Gabor filter bank to further enhance the dark regions

$$G(x, y, \sigma, \Omega, \theta, r) = \frac{1}{\sqrt{\pi\sigma}} e^{-1/2 \left[\left(\frac{d1}{\sigma} \right)^2 + \left(\frac{d2}{\sigma} \right)^2 \right]} \cos(\Omega x + \text{isin}\Omega y) \quad (4)$$

Where σ , Ω , r and θ are the variety, recurrence, angle proportion and introduction independently The improved picture is convolved with Gabor channel G focused at location(s, t) to create Gabor channel reaction γ for chose estimations of σ , Ω and θ is given in condition 5 [14].

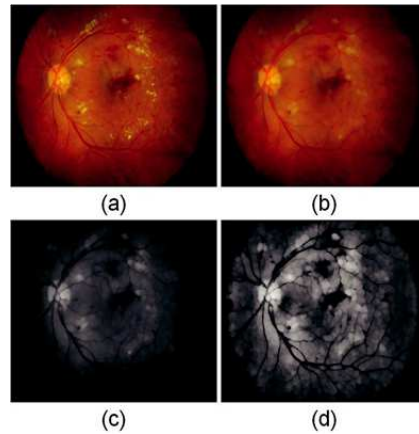


Figure 2: (a) Learned Fundus Image; (b) Maintaining Dark Areas; (c) Gray Version of (b); (d) Dark Regions Contrast Enhancement [13]

$$\chi(s, t, \sigma, \Omega, \theta, r) = \sum \sum g(x, y) G(s - x, t - y, \sigma, \Omega, \theta, r) \quad (5)$$

The Gabor channel bank reaction γ is ascertained for various introduction values with the end goal that the adjustment in point is equivalent to 450 and for every introduction most extreme reaction is put away. The channel bank based improved picture is changed over into double picture by applying reasonable edge which will return applicant dull districts. The veins additionally show up as dim areas so these applicant locales contain veins also. So as to diminish the false positive because of veins, the vascular example is isolated utilizing [15] and all vessel pixels are expelled from competitor parallel picture. Figure 3 demonstrates the after-effects of Gabor channel bank and injuries districts prior and then afterward prohibition of vascular pixels.

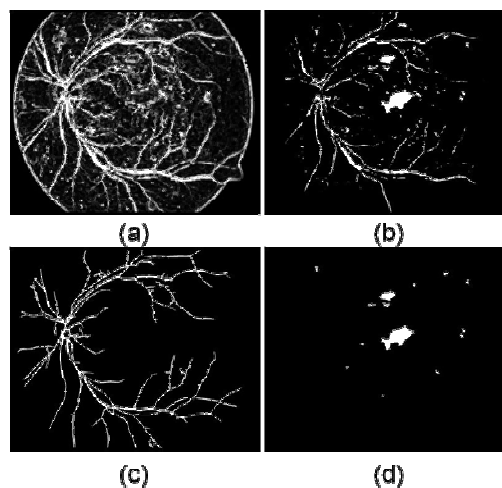


Figure 3: (a) Gabor Filter Based Enhanced Image; (b) Candidate Regions; (c) Vascular Pattern Extracted [15]; (d) Regions after Exclusion of Vascular Pixels [13]

HE and CWS show up as brilliant yellowish or whitish spots on fundus surface so they by and large named as splendid sores. The same technique is taken after for splendid injury recognition aside from a couple changes. In bight sore finding, morphological shutting is utilized to secure every single splendid locale, for example, OD and injuries like HE and CWS if present utilizing condition 7[10].

$$\zeta f^{(sB)} = \min [\max (x + b)] \quad (6)$$

Figure 4 demonstrates the consequences of shutting and improvement for extraction of splendid sore locales. Same Gabor channel manage an account with scale estimations of 2, 5 and 7 is connected on the complexity upgraded green channel picture to highlight brilliant districts. Gabor channel bank reaction for splendid injuries is given in figure-6(a) which is liable to drawing nearer to produce twofold districts for competitor sores. Here once more, the limit T2 is picked in an extremely avoiding way to acquire verging on each locale containing splendid sores however with some credible areas. The nearness of OD and it’s looking like with brilliant injuries offer ascent to false applicant districts for splendid sores. The proposed framework gathers up false district created by OD by finding and killing OD area. OD limitation and division is done utilizing our past technique clarified as a part of [16].

Figure 5 demonstrates the sectioned splendid hopeful damages previously, then after the fact leeway of OD area.

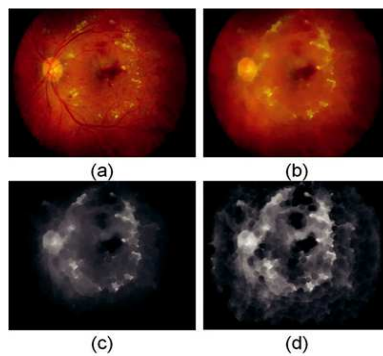


Figure 4: a) Acquired Fundus Image; b) Preserving of HE, CWS and OD Utilizing Closing Morphological Operation; c) Contrast Enhanced Green Channel Showing HE and CWS; d) Combined Gabor Filter Bank Response [29]




Figure 5: a) Gabor Filter Banks Response M_r ; b) Segmented Bright Lesions Containing Specious Regions; c) Segmented OD Region; d)Candidate Lesions after Removing Region Containing OD[13]

IV. HIGHLIGHT EXTRACTION

The competitor areas are spoken to by various elements. The depiction of elements is given in Table-1 [17].

Table 1: Highlight Description for Classification of Lesions

Feature Feature Depiction	Documentation
F1	Eccentricity: It is measure of circularity
F2	Area: It is entirety of all pixels
F3	Perimeter: Boundary that encompasses the range of competitor
F4	Edge apportions
F5	Aspect proportion: It is the proportion of real pivot to minor hub Length of competitor locale

F6 F7	These components are mean and standard deviation of pixels In hopeful district for a green channel picture
F8 F9	these components are the mean and standard deviation esteem Of improved force values
F10	Mean angle esteem for limit pixels

V. GROUPING

The three thresholding technique is utilized to characterize the hopeful areas into various sores. The strategies are connected on range of hopeful districts. It reviews the hopeful locale in any of the four classes. Utilizing this thresholding strategy, we get pictures having yellow or white spots and red or dim spots. After this outcome, it must be isolated utilizing highlight portrayal. For MA and H spots, all red or dull spot getting from segment III. Range of spots are to be discover, then we can without much of a stretch group them agreeing just region of the spot. Fundamental issue for thresholding is to choose limit level. Here we have chosen three thresholding utilizing taking after conditions.

$$T_a = (\text{Rows} * \text{Column}) / 4000 \quad (7)$$

$$I_{\text{red}} > T_a \rightarrow IR \quad (8)$$

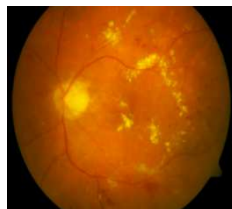
$$I_{\text{red}} < T_a \rightarrow I_{MA} \quad (9)$$

VI. Tests


For assessment purposes, we are utilized two arrangements of openly accessible retinal pictures in particular DI-ARETDB0 [19] and DIARETDB1 [20]. These two databases are simply plan to prepare the studies on DR injuries. The aggregate quantities of pictures in these databases are 219 (130 in DIARETDB0 and 89 in DIARETDB1). The anticipated databases were controlled by catching fundus pictures with 50o Field of View (FOV) and 1500×1152 determination. The pictures indicate enormous distinction in term of sores and seriousness esteem which make these databases well-suited for testing. The base truth information for these databases is had with the assistance of two space specialists. They showed complete 3576 sores with 1998 red injuries and 1578 brilliant sores shape each of the 219 pictures as clarified in table 2.

Table 2: Dataset Specification

Total	Total Lesions			
Images	MAs	H	HE	CWS
219	1242	756	1540	38



(a)



(b)

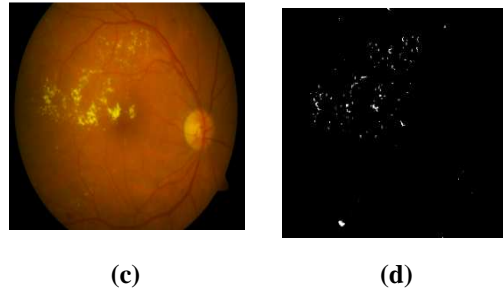


Figure 6: NPDR Lesion Segmentation: a) and c) Symbolise Real Retinal Images Whereas b) and d) Show Marked NPDR Lesions Represents MAs, H, HE and CWS Respectively

Figure 6 indicates stamped injuries by separating the sores into four classes. The activities of proposed framework are measured at hurt level utilizing affectability (Sen), specificity (Spec) and exactness (Acc) as figure of legitimacy. To analyze the execution of proposed technique, we separate the sores into two gatherings' i.e. red or dim injuries and splendid sores and co-relate the outcomes with beforehand proposed systems. Tables III and IV demonstrate the similar after-effects of different techniques with proposed strategy (PM) for red and splendid injuries individually.

Table 3: Comparative Analysis for Lesions (Mas, H, He & Cws)

Methods	Sen	Specificity	Accuracy
Walter et al. [9]	88.5	-	-
Kahai et al. [21]	100	67	-
Larsen et al. [22]	71.4	96.7	82.6
PM	92.81	99.55	99.56

VII. CONCLUSIONS

We have exhibited a keen indicative framework for identification of NPDR stages i.e. MAs, H, HE and CWS utilizing shaded retinal pictures as a part of this paper. A three phase model, involving pre-preparing, applicant sore discovery and grouping, has been proposed. The hopeful sore identification stage utilized opening and shutting, difference and Gabor channel bank based upgrade for various sores. Vein and OD pixels are disposed of in applicant location stage to diminish the quantity of influenced injuries. A point by point highlight set for every injury is framed checking diverse properties of all sores. Tables III demonstrated that the proposed technique has beaten beforehand displayed strategies as far as affectability, specificity and exactness. In spite of the fact that the proposed framework just cantered around dependable discovery of abnormalities yet the framework can be utilized for shrewd screening of diabetic retinopathy with an added substance ability of grouping the retinal picture on premise of bizarreness present in it.

REFERENCES

1. K .M. West, L.J. Erdreich and J.A. Stober, "A detailed study of risk factors for retinopathy and nephropathy in diabetes," Diabetes, vol. 29, pp. 501-508, 1980
2. E. J. Susman, W. J. Tsiaras, and K. A. Soper, "Diagnosis of diabetic eye disease," JAMA, vol. 247, pp. 3231-3134, 1982.A.Y. Alanis, B.S. Leon, E.N. Sanchez, and E. Ruiz-Velazquez, "Blood Glucose Level Neural Model for Type 1 Diabetes Mellitus Patients", International Journal of Neural Systems, vol. 21, pp. 491-504, 2011.

3. P. C. Sinthanayothin, J. F. Boyce, H. L. Cook, and T. H. Williamson. "Automated localization of the optic disc, fovea and retinal blood vessels from digital color fundus images", *Br. J. Ophthalmol.*, vol. 83, pp. 231-238, August 1999.
4. P. C. Ronald, T. K. Peng, *A textbook of clinical ophthalmology: a practical guide to disorders of the eyes and their management*, 3rd edition, World Scientific Publishing Company, Singapore, 2003.
5. R. N. Frank, "Diabetic retinopathy", *Prog. Retin. Eye Res.*, vol. 14, pp. 361-392, 1995.
6. Retinopathy Online Challenge Website. The University of Iowa and the ROC organizers [Online]. Available: <http://roc.healthcare.uiowa.edu/results.php>.
7. Niemeijer M., Ginneken B. V., M. Cree, A. Mizutani, G. Quellec, C. I. Sanchez, B. Zhang, R. Hornero, M. Lamard, C. Muramatsu, X. Wu, G. Cazuguel, J. You, A. M. Q. Li, Y. Hatanaka, B. Cochener, C. Roux, F. Karray, M. Garcia, H. Fujita, M. Abramoff, "Retinopathy online challenge: Automatic detection of microaneurysms in digital color fundus photographs", *IEEE Trans. Med. Imag.*, vol 29, pp. 185-195, 2010.
8. Quellec G., Lamard M., Josselin P. M., Cazuguel G., B. Cochener, C. Roux, "Optimal wavelet transform for the detection of microaneurysms in retinaphotographs". *IEEE Trans. on Med. Imag.* vol 27, pp. 1230-1241, 2008.
9. T. Walter, P. Massin, A. Erginay, R. Ordonez, C. Jeulin, J. Klein, "Automatic detection of microaneurysms in color fundus images", *Medical Image Analysis*, vol. 11, pp. 555-566, 2007.
10. T. Walter, J. C. Klein, P. Massin, A. Erginay, "A Contribution of Image Processing to the Diagnosis of Diabetic Retinopathy Detection of Exudates in Color Fundus Images of the Human Retina", *IEEE Transactions On Medical Imaging*, vol. 21, pp. 1236-1243, 2002.
11. Acharya U. R. , K. C. Chua, Ng, E. Y. K., Wei, W., C. Chee, "Application of higher order spectra for the identification of diabetes retinopathy stages", *Journal Med. Syst*, vol. 32, pp. 431-488, 2008.
12. A. Tariq, M.U. Akram, "An Automated System for Colored Retinal Image Background and Noise Segmentation", In *proc IEEE Symposium on Industrial Electronics and Applications*, pp. 405-409, 2010.
13. Anam Tariq , M. Usman Akram , Younus Javed "Computer Aided Diagnostic System for Grading of Diabetic Retinopathy" *IEEE Fourth International Workshop on Computational Intelligence in Medical Imaging (CIMI)* Vol. 978-1-4673-5919-1/13/c 2013.
14. J. Sung, S. Y. Bang, S. Choi, "A Bayesian Network Classifier and Hi-erarchical Gabor Features for Handwritten Numeral Recognition", *Pattern Recognition Letters*, 2005.
15. M. U. Akram, S. A. Khan, "Multilayered thresholding-based blood vessel segmentation for screening of diabetic retinopathy", *Engineering with computers*, DOI: 10.1007/s00366-011-0253-7, 2011.
16. M. U. Akram, A. Khan, K. Iqbal, W. H. Butt, "Retinal Image: Optic Disk Localization and Detection", *Image analysis and Recognition, Lecture Notes in Computer Science LNCS 6112*, pp. 40-49, 2010.
17. M. U. Akram, S. Khalid, S. A Khan, "Identification and Classification of Microaneurysms for Early Detection of Diabetic Retinopathy", *Pattern Recognition*, vol 46, pp. 107-116, 2013

18. <http://www.esat.kuleuven.be/sista/lssvmlab/>
19. Kauppi, T., Kalesnykiene, V., Kamarainen, J.K., Lensu, L., Sorri, I., Uusitalo, H., Klviinen, H., Pietil, J., “DIARETDB0: Evaluation Database and Methodology for Diabetic Retinopathy Algorithms”, Technical report, 2005.
20. Kauppi, T., Kalesnykiene, V., Kamarainen, J.K., Lensu, L., Sorri, I., Raninen A., Voutilainen R., Uusitalo, H., Klviinen, H., Pietil, J., “DIARETDB1 diabetic retinopathy database and evaluation protocol”, Technical report, 2006.
21. P. Kahai, K. R. Namuduri, H. Thompson, “A decision support framework for automated screening of diabetic retinopathy”, Int. J. Biomed. Imag., 1-8, 2006.
22. M. Larsen, J. Godt, N. Larsen, L. Andersen, H. Sjolie, A. K. Agardh, H. Kalm, M. Grunkin, D. R. Owens, “Automated detection of fundus photographic red lesions in diabetic retinopathy”, Invest Ophthalmol Vis Sci. vol. 44, pp. 761-766, 2003.

